

Optimizing Wound Healing for Cosmetic and Medical Dermatologic Procedures

Among the options for wound management is hypochlorous acid, a broad-action antimicrobial and anti-inflammatory agent.

BY ASHISH BHATIA, MD; JEFFREY HSU, MD; TODD SCHLESINGER, MD; AND ROBERT WEISS, MD

Multiple factors influence wound healing. However, three primary conditions are essential for optimal wound healing with minimal risk of scarring. First, optimal wound healing requires the eradication of pathogenic bacteria and biofilm. Second, optimal wound healing requires an excellent blood supply and proper oxygenation. Finally, the proper immunological healing factors must be present in order for the wound to heal. With these optimal healing “primers” in place, the outcome is minimal scarring, rapid healing, and good structure and function of the healed wound site.

Physicians who perform aesthetic procedures, especially energy-based treatments or injections, are particularly focused on rapid healing, minimum pain, minimum down time, and optimal appearance. A controlled wound, as created with these tools and technologies, is associated with improved healing compared to uncontrolled or traumatic wounds. Nevertheless, proper wound care serves to further support healing for optimal cosmesis. Consider that, in some cases, aesthetic physicians are creating controlled wounds with the intention to revise existing scars, and the need to support wound healing becomes evident.

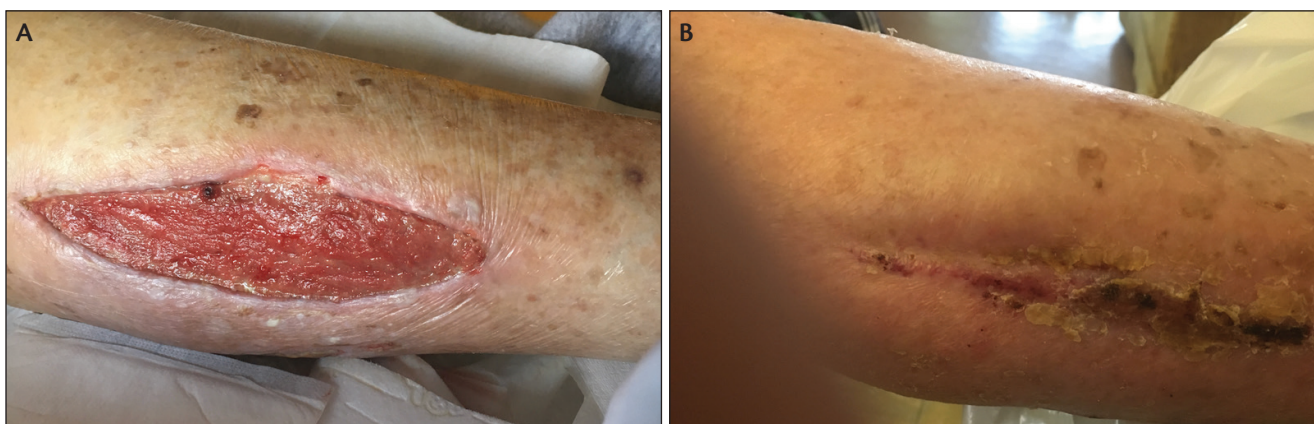
For dermatologists, wound care generally is focused on post-surgical management for biopsy and excision sites or post-procedural skincare following energy-based procedures or peels. At-home skin prep for excisions or Mohs micrographic surgery is not common. However, many patients interested in aesthetic procedures are advised to implement a skincare routine in advance of the procedure. In the aesthetic patient, retinoids and related compounds, botanical ingredients, growth factors, and antioxidants may be recommended individually or in combination, depending on the patient, the procedure, and the physician preference.

Increasingly, evidence suggests that the care of the skin immediately before a surgery or procedure and through the healing phase can have important effects on healing outcomes. For years, dermatologists have relied on certain “conventional” options for peri-procedural skincare: topical antiseptics to cleanse the skin immediately before a procedure, petrolatum ointments immediately after a procedure, and/or topical antibiotic ointments to reduce the risk of infection. Emerging evidence and experience suggests these options may not be ideal.

The antiseptic preparations most commonly used in surgery in the US are iodopovidone and chlorhexidine. Iodopovidone dyes the clothing and the hair; The smell and associated irritation are noxious for some patients. Chlorhexidine can be toxic to tissues, especially the cornea. Therefore, procedural dermatologists have grown increasingly concerned about its use. However, chlorhexidine confers certain practical benefits over betadine, and, at least historically, has been an important option. Chlorhexidine provides 48 hours—perhaps up to 72 hours—of antimicrobial effect, and it can endure being washed with blood or fluids.

Use of topical antibiotic preparations for wound care is increasingly unpopular, due to concerns about the development of bacterial resistance. Furthermore, topical antibiotics confer no activity against yeasts that reside on the skin and may infect wounds. Additionally, some topical antibiotic formulations are associated with risks for allergic contact dermatitis. The associated inflammation in the wound site is detrimental to wound healing and may contribute to scar formation, hyperpigmentation, or hypopigmentation.

Alternative approaches to wound management and infection prevention have been emerging. The use of platelet rich plasma (PRP), which is increasingly being adopted into



Courtesy of Robert A. Weiss, MD

Healing of a post-op surgical wound in a 92-year-old using Lasercyn Spray with daily dressing changes. For the first two weeks, no Lasercyn spray was used. There was no healing and patient had a wound infection that required oral antibiotics (left). Once Lasercyn spray was added to the regimen, wound healing occurred quickly without infection. No pain or itching with spray application (right).

cosmetic practices for a range of potential aesthetic benefits, was first developed as a way to support wound healing and augment the body's natural defenses against infection. The benefit of PRP is sterility, biocompatibility, and lack of toxicity. However, for dermatologic procedures, PRP is typically applied immediately after a procedure, but plays no role in long-term wound management.

Topical formulations of hypochlorous acid (HOCl) are now available for both pre-procedural skin preparation and post-procedural wound management. HOCl is a naturally-occurring, weak acid, that is produced within the neutrophil as part of the human body's innate immunity. Hypochlorous acid produced by the immune system has anti-bacterial effects. In vitro studies have demonstrated that HOCl can break down the cell wall of bacteria, spores, and many viruses. Researchers are now able to replicate HOCl in a stable topical formulation for peri-procedural use. The agent is antimicrobial, antipruritic, and non-irritating. In fact, it is even approved for application to the eyelid for management of blepharitis.

It is worth noting that topical HOCl replicates the endogenous agent produced by the human body's own immune system. It is not the same as sodium hypochlorite (NaOCl) or common bleach. While common bleach baths are sometimes recommended for management of Staph in individuals with eczema, and topical HOCl is used in eczema to similarly reduce bacterial colonization in eczema, the two are distinct chemical entities.

RETHINKING MICROBES AND BIOFILM

The influence of microbes on wound healing seems to be more complex than was once conceptualized. The long-standing goal of maintaining a sterile surgical site so that pathogens cannot proliferate to the point of frank infection lacks nuance. The presence of biofilms has at least two impor-

tant consequences. For one, we now recognize that pathologic microbes on the skin can be very difficult to eradicate. The biofilm is produced by bacteria in order to insulate and protect themselves. The formation of a biofilm favors expanding colonization and allows the bacteria to thrive, while making it difficult for antimicrobial products to actually reach the bacteria to confer an effect. In fact, there is evidence that many topically applied antibiotics may not effectively by-pass the biofilm to effectively diminish bacteria.

Additionally, the presence of the biofilm indicates sufficient concentration of microorganisms and inflammatory by-products to initiate a host response, even without signs of infection. In other words, the same inflammatory mediators that are active in fighting an obvious infection are also reactive to biofilm, suggesting a high degree of potential inflammation and associated increased risk for impaired skin healing in non-infected wounds.

Biofilm results when the microbiome falls into dysbiosis and microbes proliferate to a pathologic level. A healthy microbiome, characterized by a balance of beneficial and detrimental microbes, may be helpful in supporting skin healing. Therefore, the approach to microbe management

CLINICAL TIP: TINEA PEDIS IN DIABETICS

When patients have tinea pedis, it opens up the opportunity for superinfection with fissures. This is especially worrisome in patients who are diabetic or have venous stasis disease. Patients with onychomycosis and/or tinea pedis can use a formulation of silicone plus HOCl (Regenacyn) to apply to the foot as well to the interdigital spaces to help not only seal those fissures, but to provide antimicrobial and antibacterial effect, as well.

must be balanced. Imbalanced approaches to the microbiome may allow detrimental microbes to proliferate while beneficial microbes are diminished.

As part of the immune response to proliferating microbes, mast cells flood the wound site, contributing to inflammation. As cytokines initiate a histamine response, itching develops. Pain and itch contribute to patient discomfort. Patient scratching of the wound site is problematic. The patient may introduce microbes to the wound site by manipulating it, and scratching can cause trauma to the healing wound. Additionally, scratching can proliferate the itch/scratch cycle, leading to additional inflammation and increased risk for scar formation.

In light of this understanding of the role of biofilms and the immune responses that occur during wound healing, HOCl emerges as an attractive wound care product. It has broad antimicrobial activity but mimics the body's natural antimicrobial mechanisms, confers anti-inflammatory benefits, and is antipruritic.

WOUND MANAGEMENT IN THE DERMATOLOGY CLINIC

Surgery. When it comes to surgical procedures in the dermatology clinic, excisions generally and Mohs micrographic surgery specifically, are probably what first come to mind. Mohs surgery is associated with a low infection rate—around 0.5 to one percent in practices. However, the risk for infection is increased for patients that have squamous cell carcinomas on the lower extremities. The keratotic nature of these tumors may facilitate the harboring of bacteria. Additionally, wounds on the extremities may be associated with higher tension and poor oxygenation, both factors that argue for a comprehensive approach to wound care.

Use of HOCl for surgical prep may be preferred to use of chlorhexidine, which is potentially irritating and is drying. In fact, the inflammation induced by chlorhexidine can even interfere with histologic interpretation of Mohs specimens.

Use of petrolatum plus HOCl may be a reasonable way to

provide a moist wound healing environment at the post-surgical site and reduce infection risk. The petrolatum can be discontinued after one to two weeks, while the HOCl can be applied indefinitely. Outside of dermatology, HOCl is extensively used in diabetic foot ulcers and lower extremity ulcers to keep these ulcers clean and promote healing in a non-irritating way.

Silicone is one of the mainstays of wound care, whether via silicone gel sheets or products that are infused with silicone and are applied post-procedurally. HOCl can be applied in conjunction with silicone-based products; a formulation of silicone plus HOCl is also available (Regancyn, Intraderm).

Energy-based Procedures. Energy-based procedures, and especially fractional resurfacing and microneedling, are increasingly popular in dermatology and lead to the creation of micro-wounds. Though perhaps not overly emphasized, pre- and post-procedure cleansing and wound management are important considerations.

Dermatologists previously favored occlusive dressings, including petrolatum-based ointments, following microneedling and laser resurfacing procedures. However, these occlusive topicals may actually be comedogenic, leading to outbreaks of acne in such patients. This is especially worrisome when the patient is actually being treated for acne or acne scarring. A lighter topical formulation, such as HOCl, can provide a similar sealing benefit but without the risk for developing acne. Furthermore, since HOCl is anti-inflammatory and antimicrobial, it may further serve to reduce the risk for acne formation.

The anti-inflammatory effect of HOCl is beneficial for long-term post-laser skincare. Patients should apply HOCl topically each day until the skin is fully healed. However, continued use for another two to four weeks continues to reduce inflammation, with the potential to reduce short-term erythema and even reduce risk for long-term pigmentary alteration.

Patients can generally reinstitute make-up and skin care as soon as the skin has fully healed after a procedure, which is typically by day five to seven for most fractional ablative and other laser procedures. To minimize the risk of infection from potentially contaminated products or the risk for skin reactions, a longer period of abstinence from topical skincare may be recommended—usually about two weeks post-procedure. Hypochlorous acid topical preparations may be used in conjunction with any make-up or topical skincare or cosmeceutical regimen.

Injectables. As longer lasting fillers come to market, there is increasing concern about biofilms and the risk for delayed granuloma formation. Iodopovidone, chlorhexidine, and/or alcohol may all be used to clean the injection area before the procedure. Hypochlorous acid may be particularly useful in this setting because of its broad antimicrobial activity as well as its tolerability compared to alcohol and the other skin preps available.

COSMETIC TREATMENT TIP: MASSAGE

Following injection of neurotoxins, it is not advised to massage the injection site, as manipulation of the area may encourage the neurotoxin to spread. In such cases, an HOCl spray formulation (such as Lasercyn, Intraderm) may be indicated to cleanse the treatment area. However, when placing dermal fillers, and especially deep fillers, massage may be indicated. HOCl-based, silicone infused gel may be useful in this setting. The silicone in the formulation may provide an emollient-type effect, making it easier to massage the skin post-injection.

Of note, it is recommended with any antiseptic/antimicrobial preparation to use gauze to wipe the treatment area. This mechanical cleansing will help to remove make-up or other residue from the skin and provides a light debriding effect.

After injection, HOCl applied on the skin provides additional antimicrobial benefits and also “seals” the skin to aid healing and prevent infection.

Dr. Weiss recently treated a patient who had developed scarring after a CO₂ laser procedure performed outside his practice. After convincing the patient that fractional CO₂ laser therapy was the best option to treat the scars, he counseled the patient to apply silicone gel/hypochlorous acid. The improvement has been greater than would have been expected using standard post-operative skincare.

Silicone-based products are commonly used for individuals who are prone to develop hypertrophic or keloid scars. Itch is a major component of these scars, and a hallmark of their formation; it is theorized that scratching and manipulation of the site may contribute to scar formation. As an alternative or adjunct to steroid injections, which have numerous potential side effects, including possible atrophy and hypopigmentation, antipruritic HOCl applied topically can help to drive down the histamine cycle and stabilize mast cells.

A NEWER OPTION

The selection of an appropriate pre-procedural skin preparation agent and a suitable post-procedure wound management product will depend on multiple factors. Topically applied HOCl is emerging as an option with a broad range of potential uses. It is antimicrobial, anti-inflammatory, and antipruritic. It increases oxygenation to healing wounds and has activity against biofilm. It also has applications across a range of general dermatology conditions. HOCl is a pH neutral superoxidized agent made to emulate nature. In our clinical experience it has proven useful across the range of cosmetic and medical dermatologic procedures and also has application for a range of additional medical dermatology presentations, such as pruritus. ■

Ashish Bhatia, MD, FAAD is in private practice in Schaumburg, IL.

Jeffrey Hsu, MD, FAAD is in private practice in Schaumburg, IL.

Todd E. Schlesinger, MD, FAAD is Medical Director, Dermatology and Laser Center of Charleston in South Carolina.

Robert A. Weiss, MD, FAAD is Director, Maryland Laser, Skin & Vein Institute in Hunt Valley, MD.

